

# Unit B: Anatomy and Physiology of Poultry

## Lesson 2: Skeletal Structure of Poultry

# Terms

- caudal vertebrae
- cervical vertebrae
- digits
- femur
- fibula
- furcula
- hallux
- humerus
- illium
- ischium
- keel
- lower mandible
- pelvis
- phalanges
- pubis
- pygostyle
- radius
- rhamphotheca
- ribs
- scapula
- skull
- sternum
- synsacrum
- tarsus
- thoracic vertebrae
- tibia
- ulna
- upper mandible

I. The many bones of poultry provide structure to the body and allow for attachment of muscles.

A. Avian bones are hollow which allows them to fly.

1. Even though most chickens, ducks, geese, and turkeys can't fly, their bones are still hollow.

## B. Leg bones

1. Beginning at the body, the **femur** is the first leg bone.
2. The **fibula** is a much-reduced bone of the lower leg, while the **tibia** is the next major bone.

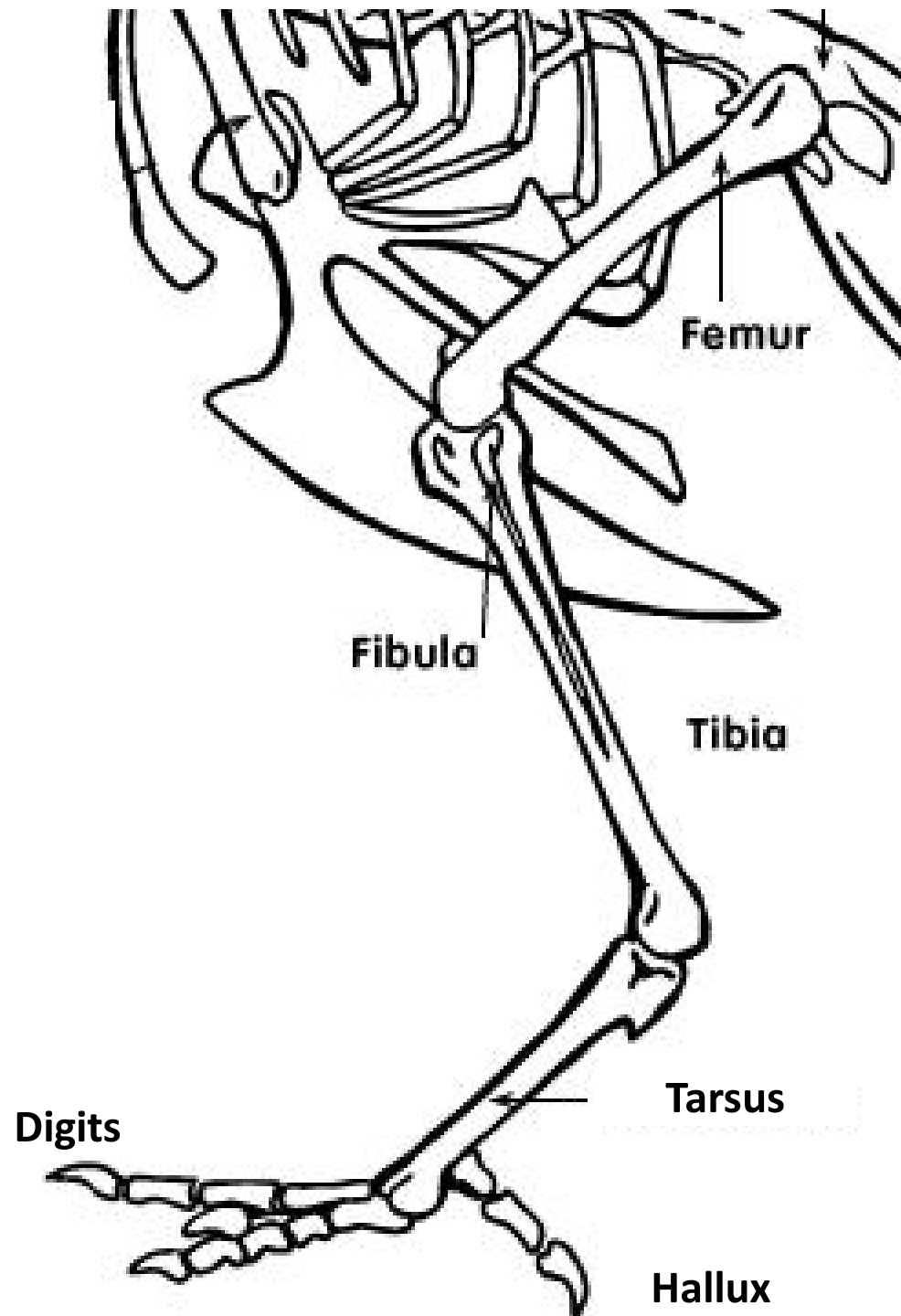
3. Next, is the elongate **tarsus**.

a. This structure is homologous to the metatarsals and tarsals in the mammalian foot.

b. However, in birds, these bones have been fused together to form what is essentially a third leg bone.

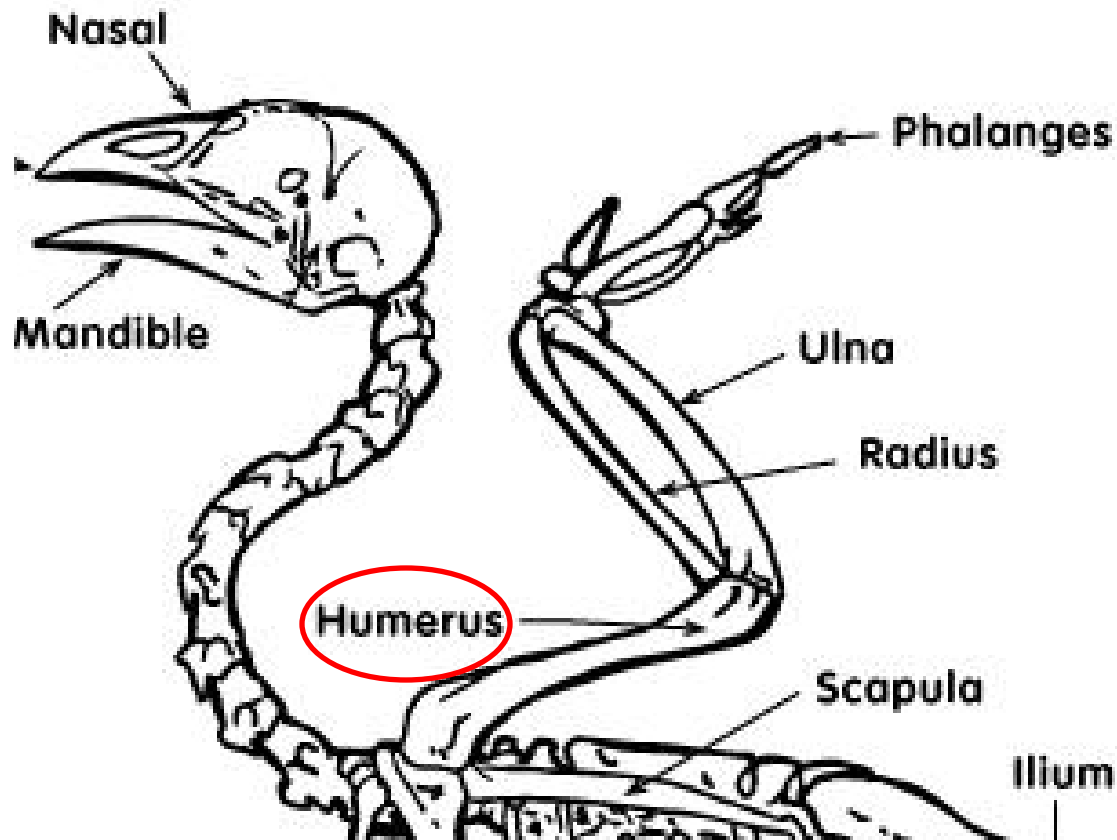
4. Birds run or walk only on their **digits** (they are technically digitigrade), each consisting of jointed **phalanges**.

a. The hind-facing digit is the first digit or **hallux**.



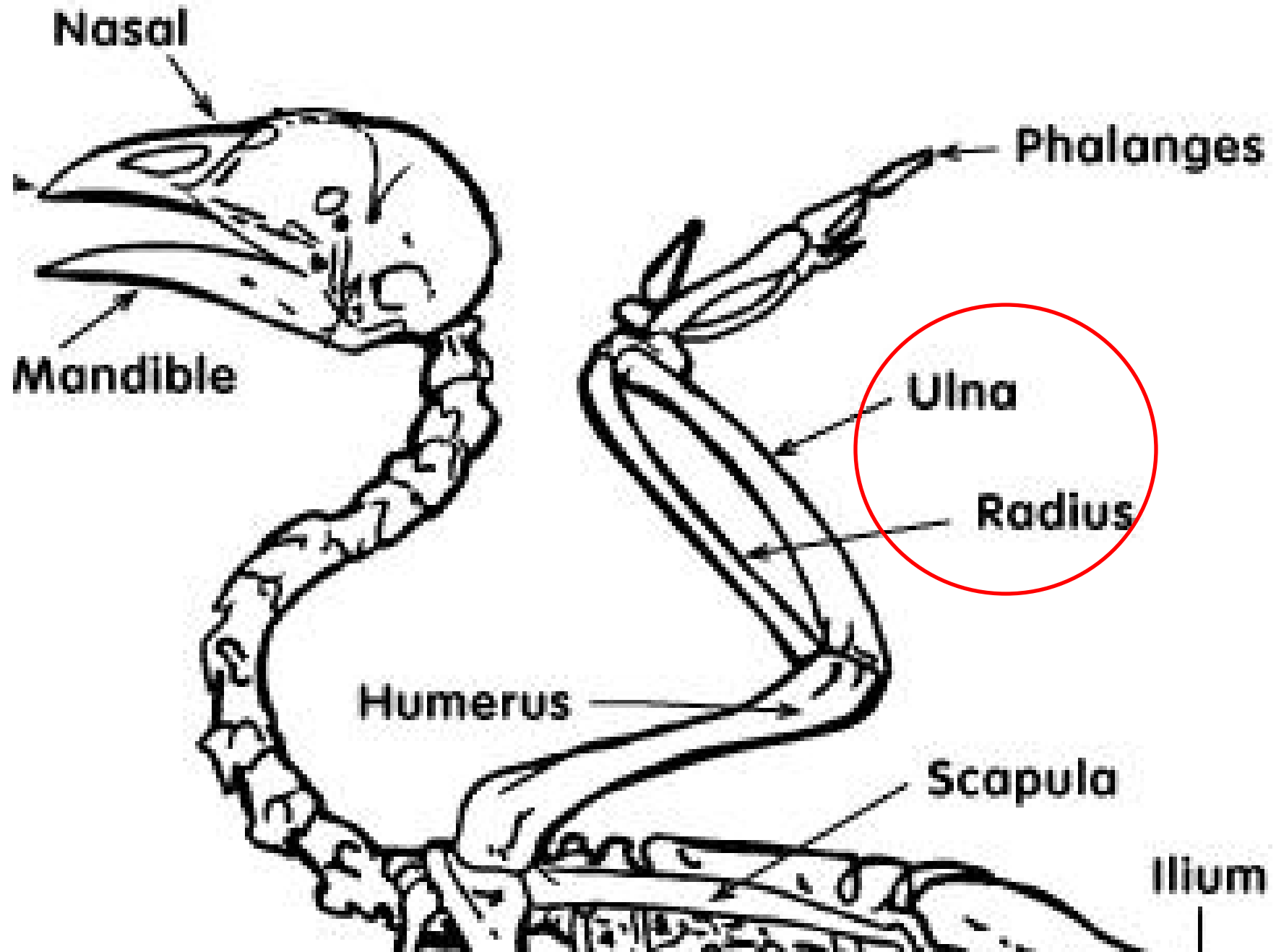
## II. Wing bones

A. The first wing bone is the **humerus**.



1. Many of the muscles involved in flight are attached to this bone, but it does not hold any flight feathers.
2. The **radius** and **ulna** comprise the forearm, and the secondary flight feathers attach to the **ulna** so take a look at that bone carefully, the area for attachment of the feathers should be obvious.
3. The remaining parts of the wing skeleton are made up by the homologues of the bones in your hand, and primarily those bones in the middle finger or third digit.
4. These bones support the primary flight feathers.





III. The bones of the spine provide support for the bones of the ribs and pelvis.

A. Skull and Vertebrae bones

1. The **skull** includes the nasals, maxilla and premaxilla which comprise the “**upper mandible**”, a term we shall use to simplify the material.
2. These structures, along with the **lower mandible** comprise the bill.

**BRAIN CASE**

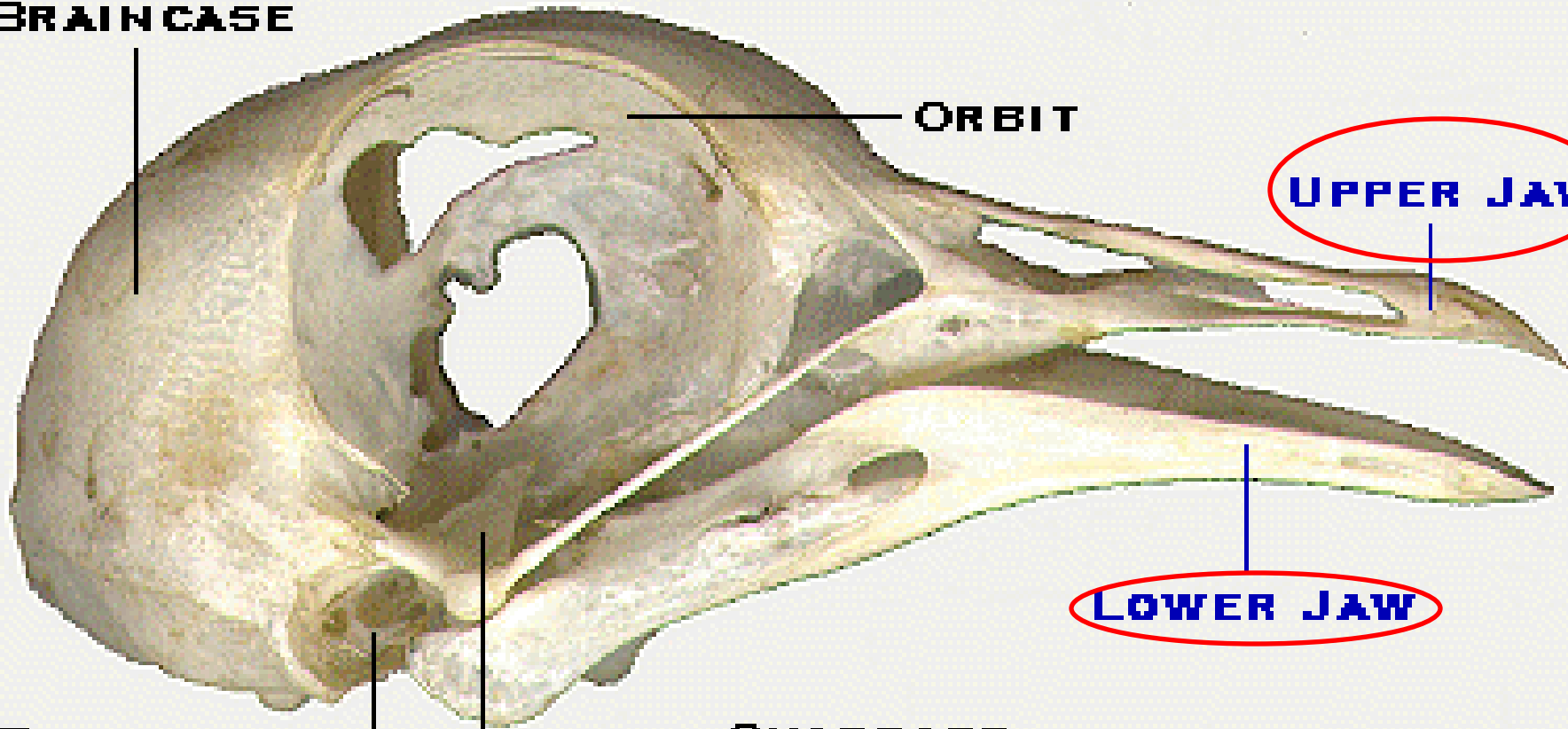
**ORBIT**

**UPPER JAW**

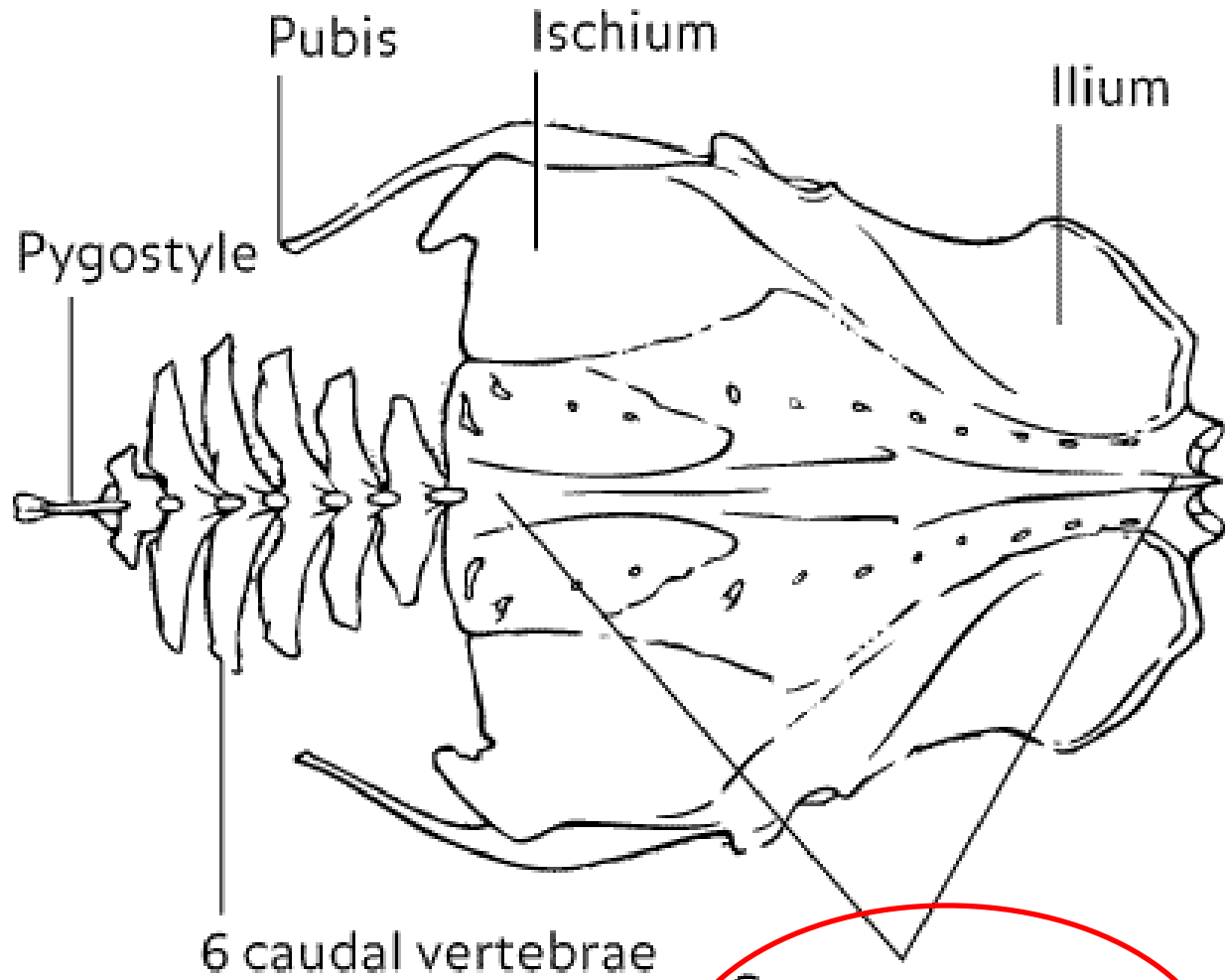
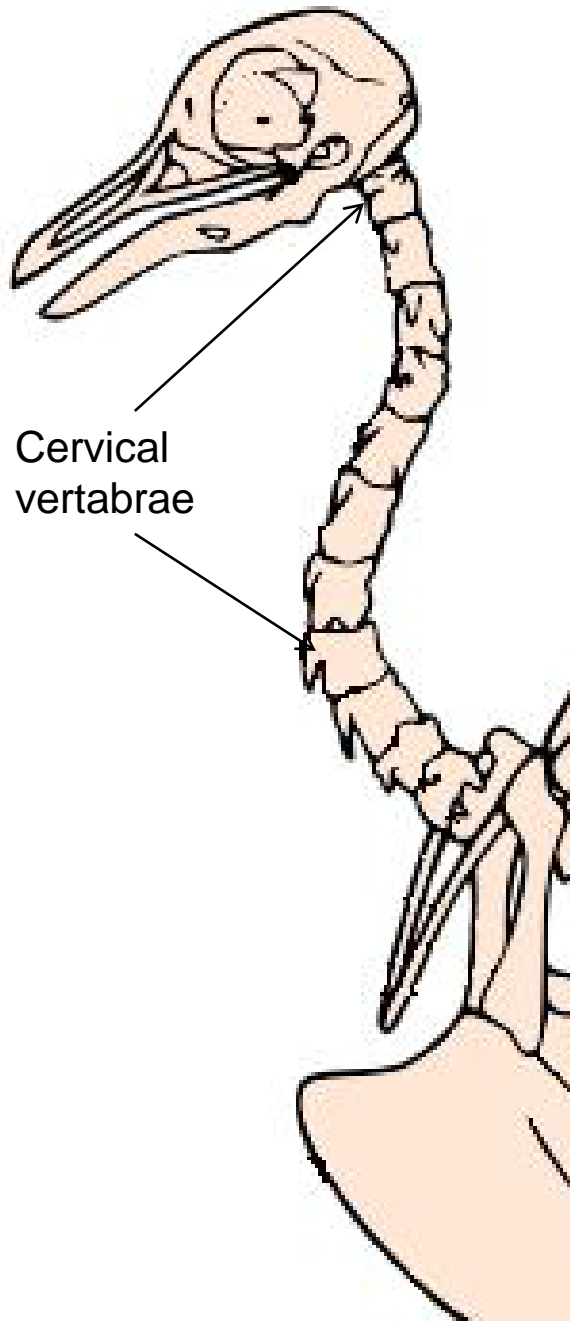
**LOWER JAW**

**EAR**

**QUADRATE**



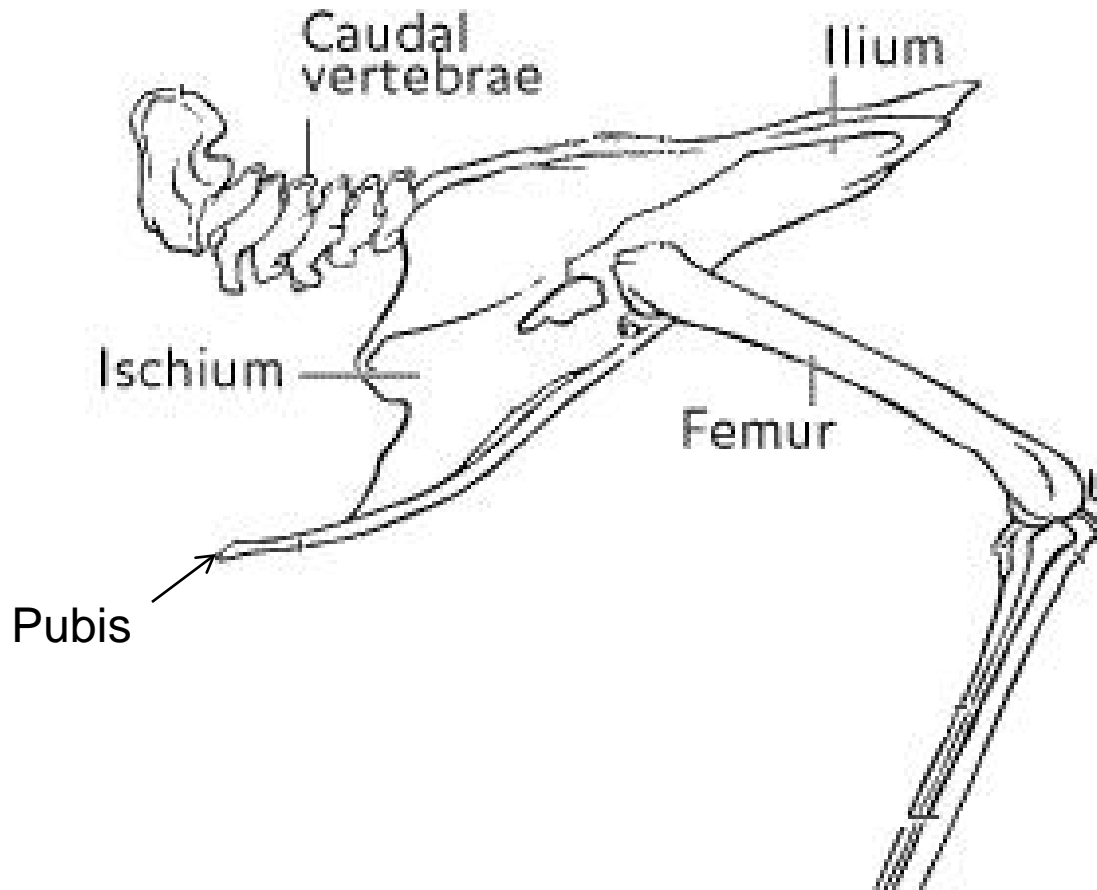
3. The vertebral column includes the **cervical vertebrae** of the neck region, **thoracic vertebrae** of the mid-body, **synsacrum** the fused sacral vertebrae, **caudal vertebrae** of the proximal part of the tail, and finally the **pygostyle** consisting of the fusion of the distal caudal vertebrae.



Synsacrum area  
(7 sacral vertebrae  
6 caudal vertebrae)

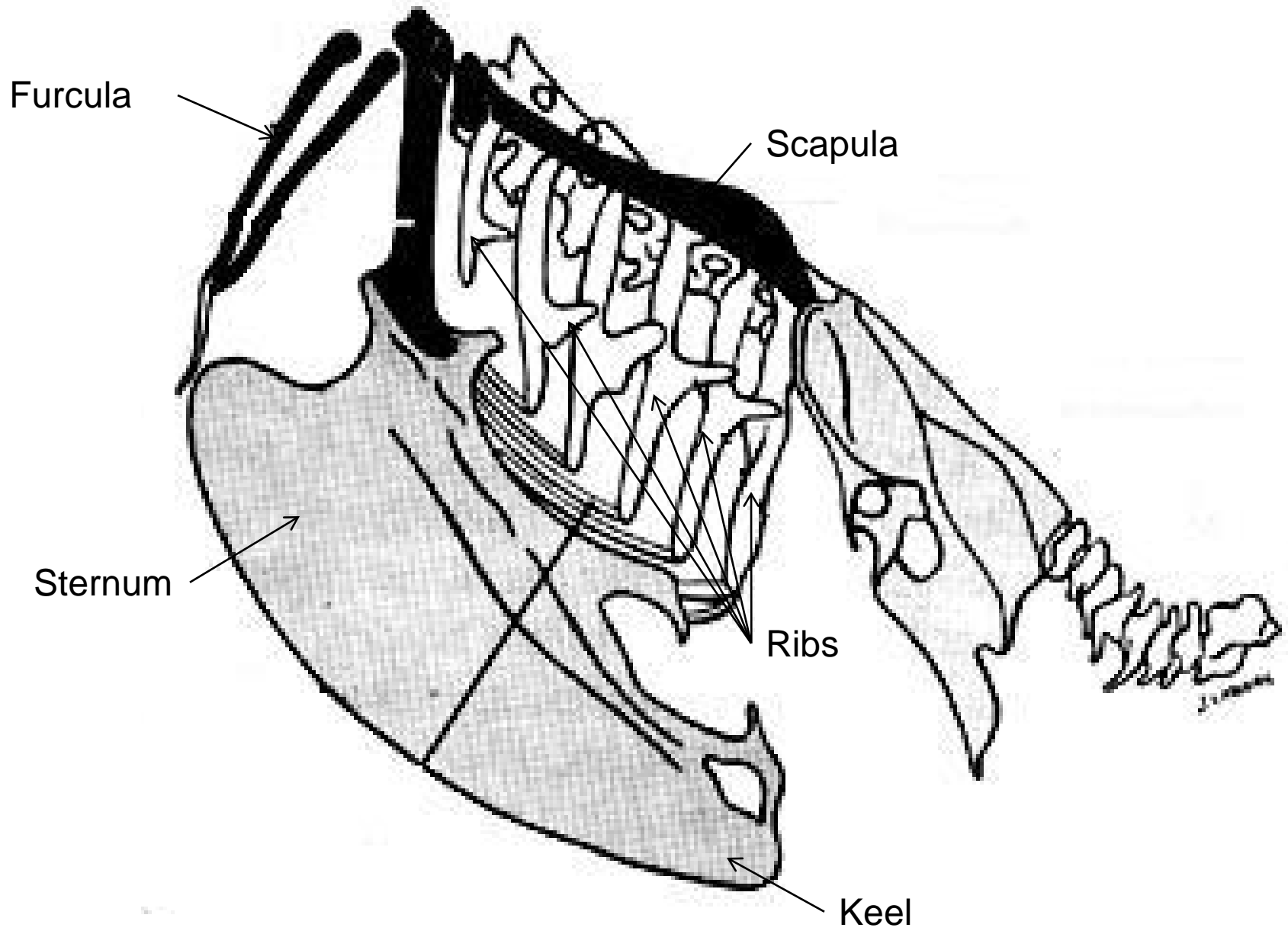
## B. Pelvic Girdle

1. The **pelvis** (**ilium**, **ischium** and **pubis**) of birds is enlarged and fused to the **synsacrum**, to provide points of attachment for upper leg muscles.



## C. Thoracic Region: (Rib cage)

1. This part of the avian skeleton has become fused, strengthened, and expanded for attachment and operation of the all-important flight muscles.
2. The **ribs** are braced against one another to provide structure to chest and give protection to the lungs and air sacs.
3. The **sternum**, with its expanded **keel**, is the main point of origin for the major flight muscles.
4. The **furcula** (wishbone) and **scapula** aid in bracing and supporting the wing. These bones have homologues in the mammalian shoulder girdle.





## IV. Beaks of birds vary widely among species.

- A. The jaw is made of bone, typically hollow or porous to conserve weight for flying.
- B. The outside surface of the beak is covered by a thin horny sheath of keratin called the **rhamphotheca**.
- C. Between the hard outer layer and the bone is a vascular layer containing blood vessels and nerve endings.
- D. The rhamphotheca can include a knob, which is found above the beak of some domesticated Chinese geese.



## Review/Summary

- What are the bones of the leg?
- What are the bones of the wing?
- What are the bones of the spine and pelvis?
- What is the beak composed of?